

## *ABC of clinical electrocardiography*

### Introduction. II—Basic terminology

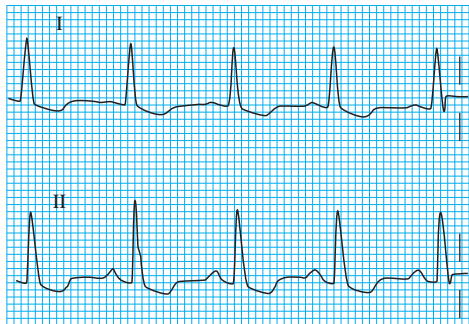Steve Meek, Francis Morris

This article explains the genesis of and normal values for the individual components of the wave forms that are seen in an electrocardiogram. To recognise electrocardiographic abnormalities the range of normal wave patterns must be understood.

## P wave

The sinoatrial node lies high in the wall of the right atrium and initiates atrial depolarisation, producing the P wave on the electrocardiogram. Although the atria are anatomically two distinct chambers, electrically they act almost as one. They have relatively little muscle and generate a single, small P wave. P wave amplitude rarely exceeds two and a half small squares (0.25 mV). The duration of the P wave should not exceed three small squares (0.12 s).

The wave of depolarisation is directed inferiorly and towards the left, and thus the P wave tends to be upright in leads I and II and inverted in lead aVR. Sinus P waves are usually most prominently seen in leads II and V1. A negative P wave in lead I may be due to incorrect recording of the electrocardiogram (that is, with transposition of the left and right arm electrodes), dextrocardia, or abnormal atrial rhythms.



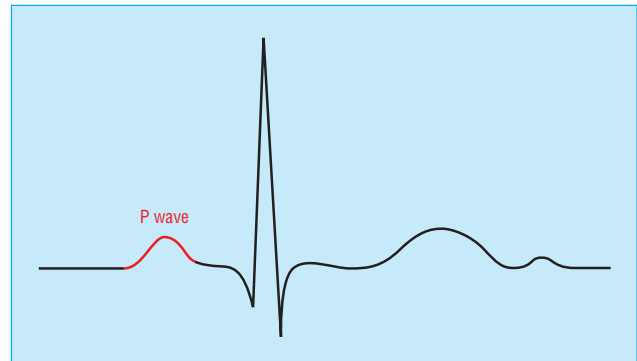
P waves are usually more obvious in lead II than in lead I

The P wave in V1 is often biphasic. Early right atrial forces are directed anteriorly, giving rise to an initial positive deflection; these are followed by left atrial forces travelling posteriorly, producing a later negative deflection. A large negative deflection (area of more than one small square) suggests left atrial enlargement.

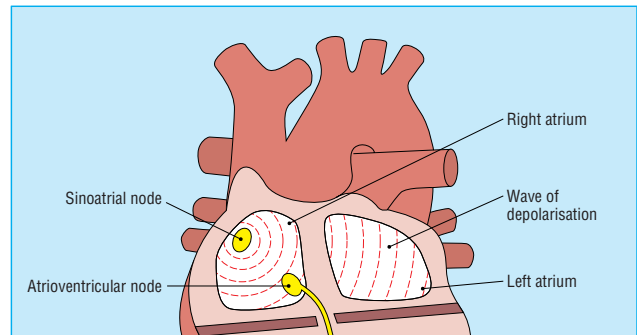
Normal P waves may have a slight notch, particularly in the precordial (chest) leads. Bifid P waves result from slight asynchrony between right and left atrial depolarisation. A pronounced notch with a peak-to-peak interval of  $> 1$  mm (0.04 s) is usually pathological, and is seen in association with a left atrial abnormality—for example, in mitral stenosis.

## PR interval

After the P wave there is a brief return to the isoelectric line, resulting in the “PR segment.” During this time the electrical impulse is conducted through the atrioventricular node, the bundle of His and bundle branches, and the Purkinje fibres.



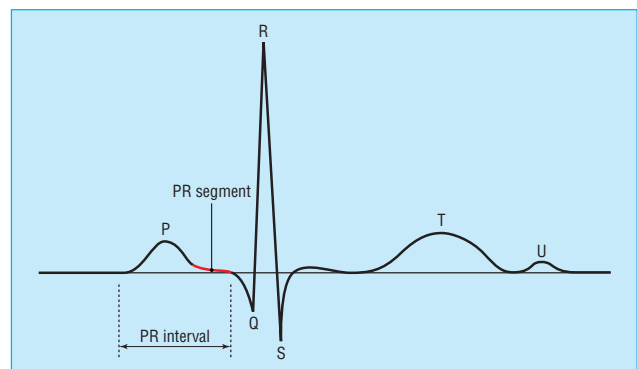
Complex showing P wave highlighted



Atrial depolarisation gives rise to the P wave

### Characteristics of the P wave

- Positive in leads I and II
- Best seen in leads II and V1
- Commonly biphasic in lead V1
- $< 3$  small squares in duration
- $< 2.5$  small squares in amplitude



Normal duration of PR interval is 0.12–0.20 s (three to five small squares)

The PR interval is the time between the onset of atrial depolarisation and the onset of ventricular depolarisation, and it is measured from the beginning of the P wave to the first deflection of the QRS complex (see next section), whether this be a Q wave or an R wave. The normal duration of the PR interval is three to five small squares (0.12-0.20 s). Abnormalities of the conducting system may lead to transmission delays, prolonging the PR interval.

## QRS complex

The QRS complex represents the electrical forces generated by ventricular depolarisation. With normal intraventricular conduction, depolarisation occurs in an efficient, rapid fashion. The duration of the QRS complex is measured in the lead with the widest complex and should not exceed two and a half small squares (0.10 s). Delays in ventricular depolarisation—for example, bundle branch block—give rise to abnormally wide QRS complexes ( $\geq 0.12$  s).

The depolarisation wave travels through the interventricular septum via the bundle of His and bundle branches and reaches the ventricular myocardium via the Purkinje fibre network. The left side of the septum depolarises first, and the impulse then spreads towards the right. Lead V1 lies immediately to the right of the septum and thus registers an initial small positive deflection (R wave) as the depolarisation wave travels towards this lead.

When the wave of septal depolarisation travels away from the recording electrode, the first deflection inscribed is negative. Thus small “septal” Q waves are often present in the lateral leads, usually leads I, aVL, V5, and V6.

These non-pathological Q waves are less than two small squares deep and less than one small square wide, and should be  $< 25\%$  of the amplitude of the corresponding R wave.

The wave of depolarisation reaches the endocardium at the apex of the ventricles, and then travels to the epicardium, spreading outwards in all directions. Depolarisation of the right and left ventricles produces opposing electrical vectors, but the left ventricle has the larger muscle mass and its depolarisation dominates the electrocardiogram.

In the precordial leads, QRS morphology changes depending on whether the depolarisation forces are moving towards or away from a lead. The forces generated by the free wall of the left ventricle predominate, and therefore in lead V1 a small R wave is followed by a large negative deflection (S wave). The R wave in the precordial leads steadily increases in amplitude from lead V1 to V6, with a corresponding decrease in S wave depth, culminating in a predominantly positive complex in V6. Thus, the QRS complex gradually changes from being predominantly negative in lead V1 to being predominantly positive in lead V6. The lead with an equiphasic QRS complex is located over the transition zone; this lies between leads V3 and V4, but shifts towards the left with age.

The height of the R wave is variable and increases progressively across the precordial leads; it is usually  $< 27$  mm in leads V5 and V6. The R wave in lead V6, however, is often smaller than the R wave in V5, since the V6 electrode is further from the left ventricle.

The S wave is deepest in the right precordial leads; it decreases in amplitude across the precordium, and is often absent in leads V5 and V6. The depth of the S wave should not exceed 30 mm in a normal individual, although S waves and R waves  $> 30$  mm are occasionally recorded in normal young male adults.

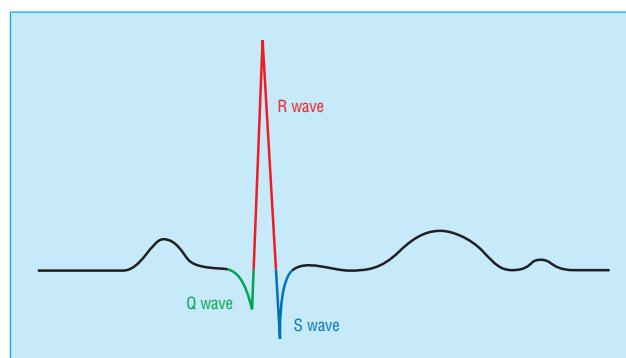
### Nomenclature in QRS complexes

*Q wave:* Any initial negative deflection

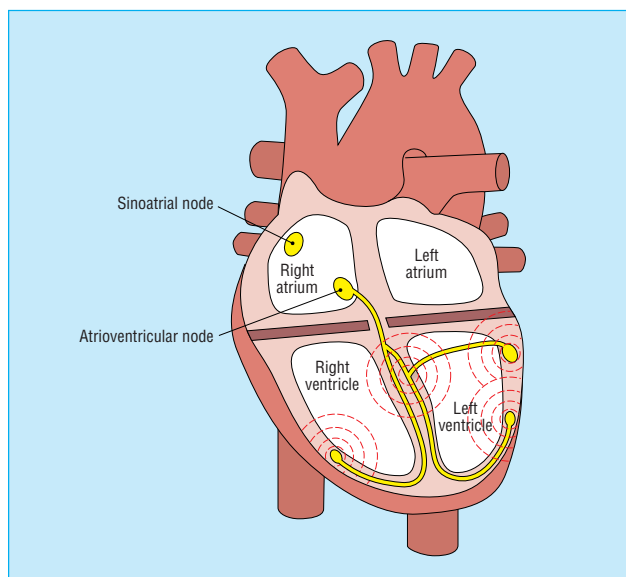
*R wave:* Any positive deflection

*S wave:* Any negative deflection after an R wave

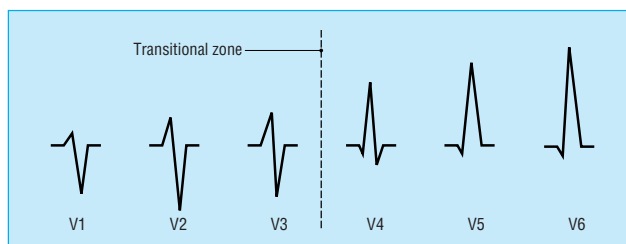
**Non-pathological Q waves are often present in leads I, III, aVL, V5, and V6**



Composition of QRS complex



Wave of depolarisation spreading throughout ventricles gives rise to QRS complex



Typical change in morphology of QRS complex from leads V1 to V6

## ST segment

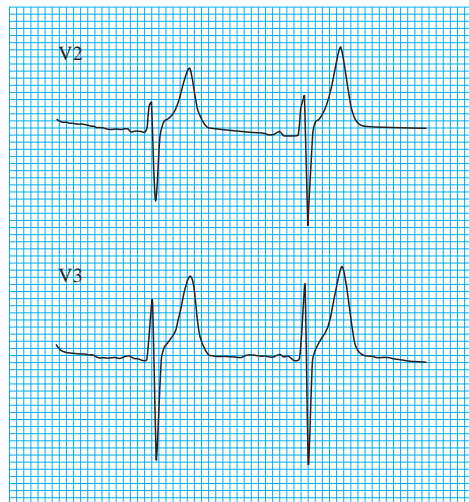
The QRS complex terminates at the J point or ST junction. The ST segment lies between the J point and the beginning of the T wave, and represents the period between the end of ventricular depolarisation and the beginning of repolarisation.

The ST segment should be level with the subsequent "TP segment" and is normally fairly flat, though it may slope upwards slightly before merging with the T wave.

In leads V1 to V3 the rapidly ascending S wave merges directly with the T wave, making the J point indistinct and the ST segment difficult to identify. This produces elevation of the ST segment, and this is known as "high take-off."

Non-pathological elevation of the ST segment is also associated with benign early repolarisation (see article on acute myocardial infarction later in the series), which is particularly common in young men, athletes, and black people.

Interpretation of subtle abnormalities of the ST segment is one of the more difficult areas of clinical electrocardiography; nevertheless, any elevation or depression of the ST segment must be explained rather than dismissed.



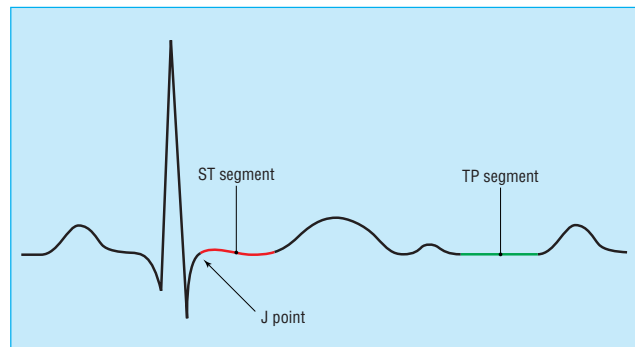
Complexes in leads V2 and V3 showing high take-off

## T wave

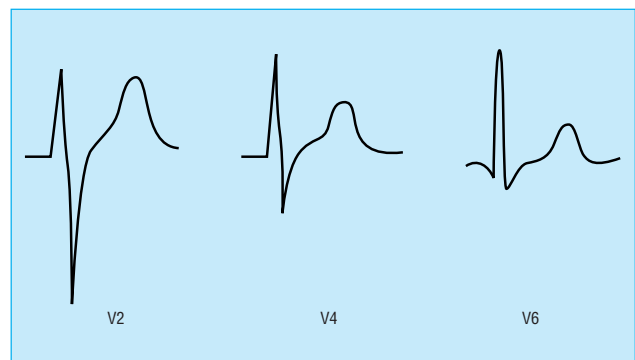
Ventricular repolarisation produces the T wave. The normal T wave is asymmetrical, the first half having a more gradual slope than the second half.

T wave orientation usually corresponds with that of the QRS complex, and thus is inverted in lead aVR, and may be inverted in lead III. T wave inversion in lead V1 is also common. It is occasionally accompanied by T wave inversion in lead V2, though isolated T wave inversion in lead V2 is abnormal. T wave inversion in two or more of the right precordial leads is known as a persistent juvenile pattern; it is more common in black people. The presence of symmetrical, inverted T waves is highly suggestive of myocardial ischaemia, though asymmetrical inverted T waves are frequently a non-specific finding.

No widely accepted criteria exist regarding T wave amplitude. As a general rule, T wave amplitude corresponds with the amplitude of the preceding R wave, though the tallest T waves are seen in leads V3 and V4. Tall T waves may be seen in acute myocardial ischaemia and are a feature of hyperkalaemia.

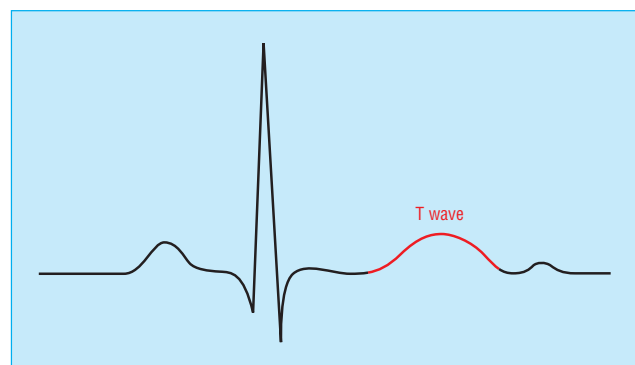


The ST segment should be in the same horizontal plane as the TP segment; the J point is the point of inflection between the S wave and ST segment



Change in ST segment morphology across the precordial leads

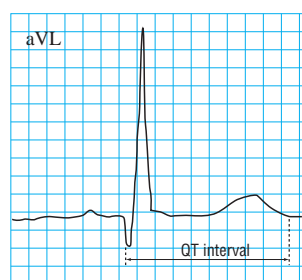
**The T wave should generally be at least 1/8 but less than 2/3 of the amplitude of the corresponding R wave; T wave amplitude rarely exceeds 10 mm**



Complex showing T wave highlighted

## QT interval

The QT interval is measured from the beginning of the QRS complex to the end of the T wave and represents the total time taken for depolarisation and repolarisation of the ventricles.



The QT interval is measured in lead aVL as this lead does not have prominent U waves (diagram is scaled up)

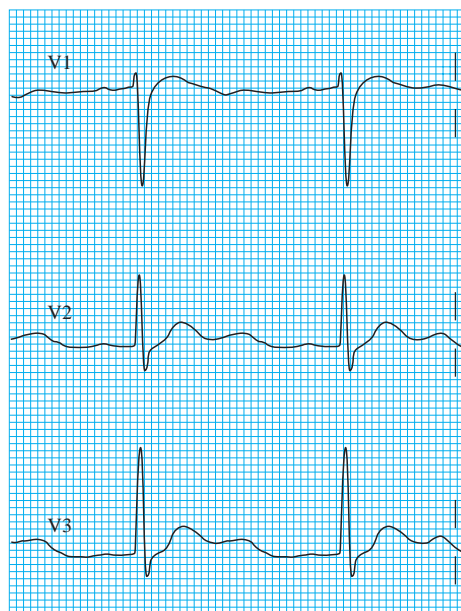
The QT interval lengthens as the heart rate slows, and thus when measuring the QT interval the rate must be taken into account. As a general guide the QT interval should be 0.35–0.45 s, and should not be more than half of the interval between adjacent R waves (R-R interval). The QT interval increases slightly with age and tends to be longer in women than in men. Bazett's correction is used to calculate the QT interval corrected for heart rate (QTc):  $QTc = QT/\sqrt{R-R}$  (seconds).

Prominent U waves can easily be mistaken for T waves, leading to overestimation of the QT interval. This mistake can be avoided by identifying a lead where U waves are not prominent—for example, lead aVL.

## U wave

The U wave is a small deflection that follows the T wave. It is generally upright except in the aVR lead and is often most prominent in leads V2 to V4. U waves result from repolarisation of the mid-myocardial cells—that is, those between the endocardium and the epicardium—and the His-Purkinje system.

Many electrocardiograms have no discernible U waves. Prominent U waves may be found in athletes and are associated with hypokalaemia and hypercalcaemia.



Obvious U waves in leads V1 to V3 in patient with hypokalaemia

Steve Meek is consultant in emergency medicine at the Royal United Hospitals, Bath.

The ABC of clinical electrocardiography is edited by Francis Morris, consultant in emergency medicine at the Northern General Hospital, Sheffield; June Edhouse, consultant in emergency medicine, Stepping Hill Hospital, Stockport; William J Brady, associate professor, programme director, and vice chair, department of emergency medicine, University of Virginia, Charlottesville, VA, USA; and John Camm, professor of clinical cardiology, St George's Hospital Medical School, London. The series will be published as a book in the summer.

BMJ 2002;324:470–3

### “A little white tablet, doctor”

Few doctors will not recognise this reply from patients asked to recall their medication. After a similarly vague history of presenting complaint, a persistent clinician might try to narrow down what the tablet is prescribed for, at least, though often (and alarmingly perhaps) this is often a fruitless exercise. There can be occasions, however, when the colour is the key after all.

When I was a senior house officer working in accident and emergency I was asked to take a telephone call from a patient wanting advice. He explained that he had gone to the high street pharmacy to collect a repeat prescription for his “rat poison.” On returning home, he was surprised to see that he seemed to have been given a different brand from his normal one, and he was now unsure what dose to take. I asked him what he normally took:

“One blue and one brown tablet, doctor.”

I calculated this as 4 mg of warfarin and explained that he should continue on this dose until his next check up, reassuring him that different pharmacies probably used slightly different packaging. He wasn't so sure. “But they're all the same colour, doctor,” he replied.

Assuming he had probably been given a supply of 1 mg brown tablets, I asked him to describe them. “Little white tablets, doctor.”

Now concerned and puzzled, I advised him to bring them to the department as he lived locally. Sure enough, in a new bottle marked “Warfarin—take as directed by your doctor” were about 50 small white tablets with a “5” embossed on them. We identified them as bendrofluzide and immediately alerted the pharmacy about the dispensing error.

Thankfully, to my knowledge, the other potentially more catastrophic half to this story never emerged—that is, the patient who agonised over which colour of his new brand of “water pills” to take first, the brown, the blue, or the pink.

Martin Turner *research fellow in neurology, King's College London.*

We welcome articles up to 600 words on topics such as *A memorable patient, A paper that changed my practice, My most unfortunate mistake*, or any other piece conveying instruction, pathos, or humour. If possible the article should be supplied on a disk. Permission is needed from the patient or a relative if an identifiable patient is referred to. We also welcome contributions for “Endpieces,” consisting of quotations of up to 80 words (but most are considerably shorter) from any source, ancient or modern, which have appealed to the reader.